




Disponible en ligne sur
 ScienceDirect
www.sciencedirect.com

Elsevier Masson France

www.em-consulte.com



CLINICAL CASE

Prenatal diagnosis and prognosis of triple X syndrome: 47, XXX

Diagnostic prénatal et pronostic du syndrome triple X : 47, XXX

H. Ben Hamouda^{a,*}, N. Mkacher^a, H. Elghezal^b, H. Bannour^c,
M. Kamoun^a, H. Soua^a, A. Saad^b, M.M. Souissi^c, M.T. Sfar^a

^a Neonatal Unit, Department of Pediatrics, Tahar Sfar University Hospital, 5111 Mahdia, Tunisia

^b Department of Cytogenetic and Biology of Reproduction, Farhat Hached University Hospital, 4000 Sousse, Tunisia

^c Department of Obstetrics and Gynaecology, Tahar Sfar University Hospital, 5111 Mahdia, Tunisia

Received 21 February 2009 ; received in revised form 9 July 2009; accepted 6 August 2009

KEYWORDS

Triple X syndrome;
Prenatal diagnosis;
Prognosis

Summary Triple X syndrome is a relatively common sex chromosomal abnormality occurring in 0,1% of live-born female infants. Most of these infants have a normal phenotype and only a few cases with 47,XXX karyotype have congenital malformations. We report three cases of triple X syndrome that were diagnosed prenatally by genetic amniocentesis for advanced maternal age and have been observed from birth to age of 3 to 12 years. A description of their growth and development is presented. The birth weight was normal in all patients and one of them had facial dysmorphism with right microphthalmia and auricular septal defect. During the first 2 years of life, the neuromotor development of these infants was not distinguishable from chromosomally normal children. By 3 years of age, two patients have a moderate developmental delay in speech and language. One girl 12-year-old had normal schooling. The diagnosis of the triple X syndrome can be never made because clinical demonstrations are not rather important to arouse the demand of a karyotype. Prenatal diagnosis is often made in front of the advanced maternal age. Expectant parents must be counseled as to the significance of this 47,XXX karyotype and prognostic information must be given.

© 2009 Published by Elsevier Masson SAS.

MOTS CLÉS

Syndrome triple X ;
Diagnostic prénatal ;
Pronostic

Résumé Le syndrome triple X est une anomalie chromosomique relativement fréquente qui touche 0,1 % des filles nées vivantes. La plupart de ces filles ont un phénotype normal et seulement quelques cas ont des malformations congénitales. Nous rapportons trois cas de syndrome triple X diagnostiqués en prénatal par l'étude du caryotype par amniocentèse réalisée devant l'âge maternel avancé et qui ont été observés de la naissance jusqu'à l'âge de trois à 12 ans avec une description de leur croissance et de leur développement psychomoteur. Le poids de naissance était normal dans tous les cas et un seul avait une dysmorphie faciale avec

* Corresponding author.

E-mail address: hechmi.benhamouda@rns.tn (H. Ben Hamouda).

une microphthalmie droite et une communication interauriculaire. Pendant les deux premières années de vie, le développement psychomoteur de ces filles n'était pas distinguable des enfants normaux. À l'âge de trois ans, deux patientes avaient un retard modéré du développement du langage. Une fille âgée de 12 ans avait une scolarité normale. Le diagnostic du syndrome triple X peut ne jamais être fait car les manifestations cliniques ne sont pas importantes pour susciter la demande d'un caryotype. Le diagnostic prénatal est souvent fait devant l'âge maternel avancé. Les parents d'enfant triple X doivent être conseillés concernant la signification de ce syndrome et son pronostic.

© 2009 Publié par Elsevier Masson SAS.

Introduction

TripleX syndrome is a sex chromosomal abnormality that involves the presence of three sex chromosomes resulting in 47,XXX karyotype [1]. The numerical abnormality occurs as a result of nondysjunction in meiosis I. Approximately 90% of these cases are of maternal origin and 10% of paternal origin. The frequency of 47,XXX diagnosed by genetic amniocentesis is estimated to be 0,1% of live-born female infants which is approximately equivalent to its incidence in the newborn population [2]. Postnatal diagnosis is difficult because most of these cases have a normal phenotype and do not manifest as structural anomaly. Only a few cases with 47,XXX karyotype have congenital malformations reported in the literature [3]. Prenatal detection of tripleX syndrome poses problems in genetic counseling. We report here three cases of tripleX syndrome that were diagnosed prenatally and we remind the clinical and evolutionary particularities of this sex chromosome aneuploidy.

Case reports

Case 1

Chaima, a term female infant was delivered at 38 weeks of gestation to a 40-year-old woman, followed in our neonatal consultation for triple X syndrome prenatally diagnosed with a karyotype by genetic amniocentesis for advanced maternal age. There was no history of consanguinity and had she




Figure 1 Karyotype of the patient 1 showing 47,XXX.
Caryotype de la patiente 1 : 47,XXX.

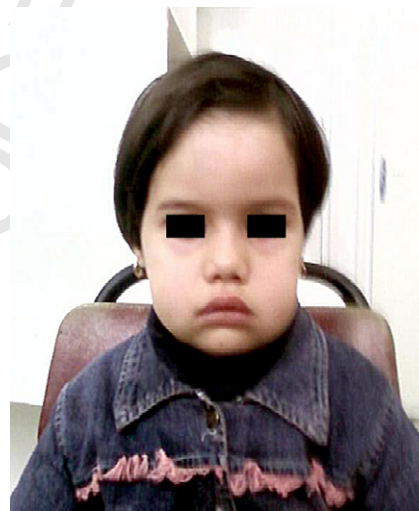

Figure 2 Chaima at 4 years of age.
Chaima à l'âge de quatre ans.

two other children in good health. The woman was counseled about the prognosis of this condition, and she decided to continue with the pregnancy. The infant was delivered vaginally. Apgar scores were 8 and 10 at one and five minutes, respectively. The birth weight was 3000 g, the length 51 cm and the head circumference was 35 cm. The neonatal examination revealed no structural malformations or dysmorphic features. The genitalia were of normal female. The neonatal course was uneventful. Ophthalmologic examination, abdominal and transfontanel ultrasound were normal. Postnatal fetal blood karyotyping confirmed the diagnosis of 47,XXX (Fig. 1). By 3 years of age, the patient has a moderate developmental delay in speech and language. Examination up to 4 years of age revealed normal developmental milestones and no abnormal features (Fig. 2).

Case 2

Malek, a term female infant was delivered at 40 weeks of gestation to a 44-year-old woman. There was no history of consanguinity and the pregnancy was uncomplicated. The woman had karyotype by genetic amniocentesis for advanced maternal age that revealed 47,XXX. The morphologic ultrasound examination was performed, and revealed no fetal abnormalities. The woman decided to continue the pregnancy after being counseled about the prognosis. The

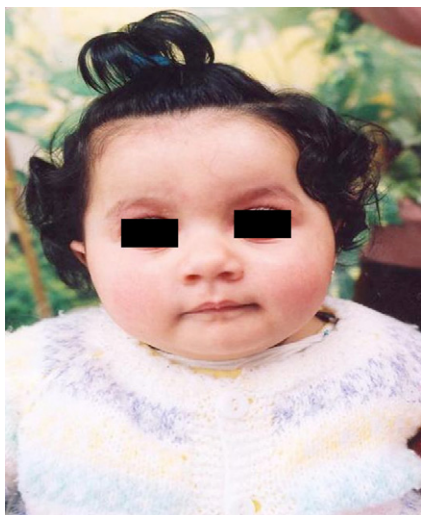

Figure 3 Malek at 3 years of age.
Malek à l'âge de trois ans.

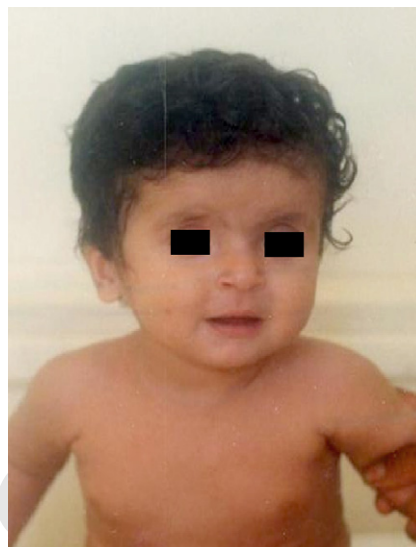

Figure 4 Sarra at 2 months of age.
Sarra à l'âge de deux mois.

93 infant was delivered by caesarian. Apgar scores were 5 and
94 7 at one and five minutes, respectively. The birth weight
95 was 3150g, the length 50cm and the head circumference
96 was 36 cm. The neonatal examination revealed no structural
97 malformations or dysmorphic features. The genitalia
98 were of normal female. The neonatal course was uneventful.
99 Abdominal and transfontanel ultrasound were normal.
100 Postnatal fetal blood karyotyping confirmed the diagnosis
101 of 47, triple X. Examination up to 3 years of age revealed
102 normal developmental milestones and no abnormal features
103 (Fig. 3).

104 Case 3

105 Sarra, a term female infant was delivered at 38 weeks of
106 gestation to a 36-year-old woman. There was consanguinity
107 parental and she had three other children in good health.
108 The pregnancy was uncomplicated. The woman had karyo-
109 type by genetic amniocentesis for advanced maternal age
110 that revealed 47, XXX. The woman was counseled about the
111 prognosis of this condition, and she decided to continue
112 with the pregnancy. The infant was delivered by caesarian.
113 Apgar scores were 5 and 7 at one and five minutes, respec-
114 tively. The birth weight was 3750g, the length 50 cm and
115 the head circumference was 35 cm. The neonatal examina-
116 tion revealed facial dysmorphism with right microphthalmia,
117 hypertelorism, low set ears and a systolic murmur meso-
118 diac (Fig. 4). Ophthalmologic examination showed an
119 Q1 ectopic pupil more marked with the left eye, corneal scar
120 with a divergent squint of the right eye. Abdominal and
121 transfontanel ultrasound were normal. Echocardiography
122 showed a large auricular septal defect. Postnatal fetal
123 blood karyotyping confirmed the diagnosis of 47, triple X. By
124 3 years of age, the patient had a moderate developmental
125 delay in speech and language. She was operated at the age
126 of 5 years for the large auricular septal defect. Examina-
127 tion up to 12 years of age revealed normal developmental
128 milestones and no abnormal features. She keeps a right
129 microphthalmia and a ptosis (Fig. 5).



Figure 5 Sarra at 12 years of age.
Sarra à l'âge de 12 ans.

Discussion

The first 47, triple X karyotype was described by Jacobs et al. in 1959 as the "super female", although in most cases these females with an extra X chromosome were identified in hospitals for the mentally subnormal [1]. Female infants with 47, triple X are relatively common, occurring in 0,1% of live born female infants [2]. Most of these infants have a normal phenotype like in our cases 1 and 2. Only a few cases with 47, triple X karyotype have congenital malformations reported in the literature [3–6]. Our case 3 arises from phenotypically normal parents, had facial dysmorphism with right microphthalmia, hypertelorism, low set ears and a large auricular septal defect. However, there is no relation between the consanguinity and the phenotype of 47, triple X karyotype reported in the literature.

There are limited reports on the prenatal diagnosis of 47,XXX. The indication for cytogenetic studies in the prenatally diagnosed cases of 47,XXFX are, generally, either advanced maternal age or after the detection of abnormal findings on a prenatal fetal ultrasound examination as oligohydramnios, fetal hydrops, intraoral mass, cleft lip and palate, postaxial polydactyly, syndactyly, bronchogenic cyst, dysplastic kidneys [3–6]. Recently, a duodenal atresia diagnosed prenatally by ultrasound scan was reported in an infant with triple X syndrome [7]. The cases that were diagnosed postnatally occurred as the result of the detection of various congenital anomalies, mainly of the genitourinary tract as ambiguous genitalia, ovarian dysgenesis, exstrophy of the cloaca, renal agenesis [6].

It has been established that sex chromosome aneuploidy increases with increasing maternal age and is detected after a triple-marker serum-screening test (maternal serum alpha fetoprotein, β human chorionic gonadotropin and unconjugated estriol). The results of which are positive for Down syndrome, at a higher rate than expected in the general population [8]. However, in reviewing the data from the large Down syndrome screening trials and from isolated case reports of 47, triple X, we found five cases of prenatal diagnosis of 47, triple X where the indication for invasive testing was a triple-marker serum screening that indicated a high risk of Down syndrome [3,9–11]. In our patients the prenatal diagnosis has been established only by genetic amniocentesis for advanced maternal age.

A single umbilical artery has been associated with malformations of all major organ systems and chromosomal defects. When this anomaly was detected on a prenatal ultrasound examination, a detailed search for other associated fetal anomalies is performed and prenatal fetal karyotyping usually is offered. We found only two reports of a single umbilical artery that was associated with the diagnosis of 47, triple X [3,12]. One fetus was aborted at 22 weeks of gestation for severe oligohydramnios and bilateral cystic dysplastic kidneys revealed by the obstetric sonogram, and postmortem examination detected the single umbilical artery along with multiple other associated anomalies [12]. We found only one report of prenatal diagnosis of 47, triple X after ultrasound detection of a single umbilical artery with no other congenital malformations [3]. However, the ultrasound abnormalities leading to discovery of triple X syndrome are extremely rare and this syndrome is often a surprising genetic diagnosis.

Concerning the prenatal diagnosis of 47, triple X fetus, parents of our three cases were informed about the risk of recurrence and the necessity to make a karyotype by genetic amniocentesis for the next pregnancies. Expectant parents in whom 47, triple X has been diagnosed in utero need to be counseled as to the significance of this karyotype, and prognostic information must be given. At birth, 47, triple X girls are usually normally developed, but their average birth weight is slightly lower and their head circumference is smaller than that of girls with normal chromosomes. Cephalometric analysis of 47, triple X females suggests that an extra X chromosome causes craniofacial growth reduction [13]. In the first year of life, 47, triple X infants were not generally distinguishable from chromosomally normal children, even though there was a slight delay in neuromotor development. By two years of age, develop-

mental delays in speech and language often became evident, and speech therapy was often necessitated in the preschool years. Early school problems included speech and language deficiencies, lack of coordination, poor academic performance, and immature behavior persisted throughout the school years. By high school age, a 47, triple X girl was generally tall and often subject to somatic complaints [14]. The unbalanced chromosome constitution in 47, triple X females creates some characteristic phenotypic features as an increase in height due to an increased leg length, small head circumference, increased tooth enamel thickness, and reduced linear growth, and increased angles within the craniofacial complex [13]. The sexual development and menarche were generally normal, but females' infants with 47, triple X have also been reported to experience delayed menarche and premature ovarian failure associated with autoimmune disease [2,15,16]. Shies became pregnant without difficulty and almost all their children have normal karyotypes. Triple X women usually have normalized ovaries with regular function and no increased risk for ovarian malignancies. Two cases of triple X syndrome with ovarian malignancies have been reported, a 24-year-old patient with unilateral dysgerminoma of the right ovary and hypoplastic left ovary, and a 17-year-old patient with gonadal dysgenesis complicated by adnexal torsion with a mucinous cystadenoma and a hypoplastic uterus [17,18].

Conclusion

We conclude that prenatal diagnosis of 47, triple X underlines the importance of discussing the sex chromosome abnormalities during the genetic counseling after an abnormal triple screen test or ultrasound examination. However, the ultrasound abnormalities leading to discovery of triple X syndrome are extremely rare and this syndrome is often a surprising genetic diagnosis. Health care professionals must therefore be prepared to give expectant parents a developmental prognosis of a fetal 47, triple X karyotype. Accurate and objective information regarding the impact of the supernumerary X, however, has been difficult to determine.

References

- [1] Jacobs PA, Baikie AG, Court-Brown WM, MacGregor TN, Maclean N, Harnden DG. Evidence for the existence of the human. *Lancet* 1959;2:423–5.
- [2] Simpson JL, Elias S. Sex chromosomal polysomies (47, XXY; 47, XYY; 47, XXX), sex reversed (46, XX) males, and disorders of the male reproductive ducts. In: Simpson JL, Elias S, editors. *Genetics in obstetrics and gynecology*. Philadelphia: Saunders; 2003. p. 323–41.
- [3] Khoury-Cotlado F, Wehbeh AN, Fisher AJ, Bombard AT, Weiner Z. Prenatal diagnosis of 47, XXX. *Am J Obstet Gynecol* 2005;192:1469–71.
- [4] Jagadeesh S, Jabeen G, Bhat L, Vasikarla M, Suresh A, Seshadri S, et al. Triple X syndrome with rare phenotypic presentation. *Indian J Pediatr* 2008;75:629–31.
- [5] Kim ES, Gross TL. Prenatal ultrasound detection of a congenital epulis in a triple X female fetus: a case report. *Prenat Diagn* 1999;19:774–6.
- [6] Lin HJ, Ndirforchu F, Patell S. Exstrophy of the cloaca in a 47, XXX child: review of genitourinary malformations in triple X patients. *Am J Med Genet* 1993;45:761–3.

- 266 [7] Rolle U, Linse B, Glasow S, Sandig KR, Richter T, Till H. Duodenal
267 atresia in an infant with triple X syndrome: a new associated
268 malformation in 47, triple X. *Birth Defects Res A Clin Mol Teratol*
269 2007;79:612–3.
- 270 [8] Haddow JE, Palomaki GE, Knight GJ, Cunningham GC, Lustig
271 LS, Boyd PA. Reducing the need for amniocentesis in women
272 35 years of age or older with serum markers for screening. *N*
273 *Engl J Med* 1994;330:1114–8.
- 274 [9] Kellner LH, Weiss RR, Weiner Z, Neuer M, Martin GM, Schulman
275 H, et al. The advantages of using triple-marker screen-
276 ing for chromosomal abnormalities. *Am J Obstet Gynecol*
277 1995;172:831–6.
- 278 [10] Haddow JE, Palomaki GE, Knight GJ, Williams J, Pulkkinen
279 A, Canick JA, et al. Prenatal screening for Down's syn-
280 drome with the use of maternal serum marker. *N Engl J Med*
281 1992;327:588–93.
- 282 [11] Benn PA, Horne D, Briganti S, Greenstein RM. Prenatal diag-
283 nosis of diverse chromosome abnormalities in a population of
284 patients identified by triple-marker testing as screen positive
285 for Down syndrome. *Am J Obstet Gynecol* 1995;173:496–501.
- 286 [12] Rembouskos G, Cicero S, Longo D, Sacchini C, Nicolaidis
KH. Single umbilical artery at 11–14 weeks' gestation:
relation to chromosomal defects. *Ultrasound Obstet Gynecol*
2003;22:567–70.
- [13] Krusinskie V, Alvesalo L, Sidlauskas A. The craniofacial complex
in 47, XXX females. *Eur J Orthod* 2005;27:396–401.
- [14] Perrotin F, Guichet A, Marret H, Potin J, Body G, Lansac
J. Devenir prénatal des anomalies des chromosomes sexuels
diagnostiquées pendant la grossesse : analyse rétrospective de
47 cas. *J Gynecol Obstet Biol Reprod* 2000;29:668–76.
- [15] Rosa RF, Dibi RP, Picetti Jdos S, Rosa RC, Zen PR, Graziadio
C. Amenorrhea and X chromosome abnormalities. *Rev Bras*
Ginecol Obstet 2008;30:511–7.
- [16] Goswami R, Goswami D, Kabra M, Gupta N, Dubey S, Dad-
hwal V. Prevalence of the triple X syndrome in phenotypically
normal women with premature ovarian failure and its associa-
tion with autoimmune thyroid disorders. *Fertil Steril* 2003;80:
1052–4.
- [17] Kemp B, Hauptmann S, Schroder W, Amo-Takyi B, Leeners B,
Rath W. Dysgerminoma of the ovary in a patient with triple X
syndrome. *Int J Gynecol Obstet* 1995;50:51–3.
- [18] Lee JH, Kim KS, Cho YG. A case of torsion of a mucinous cys-
tadenoma in triple X syndrome with pure gonadal dysgenesis.
Arch Gynecol Obstet 2006;274:174–7.

UNCORRECTED PROOF